IMAGES in PAEDIATRIC CARDIOLOGY

Invited article **Aggoun Y, Beghetti M. Noninvasive assessment of arterial function in children: clinical applications. Images Paediatr Cardiol 2002;13:12-18**

Service de Cardiologie Pédiatrique, Hôpital Necker, Enfants-Malades, Paris, France and Unité INSERM 0016 and Unité de cardiologie Pédiatrique, Département de Pédiatrie, Genève, Hôpital des Enfants, Genève, Suisse

MeSH

Vascular echography	Mechanical artery properties	Intima media thickness
Endothelial function	Pulse wave analysis	Pulse wave velocity

Abstract

Non invasive methods to assess arterial function are widely used in adults. The development and progression of arterial vascular disease is a multifactorial process that can start early in life, thus even in a pediatric population. Risk factors for cardiovascular disease mediate their effects by altering the structure, properties and function of wall and endothelial components of the arterial blood vessels. The ability to detect and monitor sub-clinical damage, representing the cumulative and integrated influence of risk factors in impairing arterial wall integrity, holds potential to further refine cardiovascular risk stratification and enable early intervention to prevent or attenuate disease progression. Measurements that provide more direct information in relation to changes in arterial wall integrity clearly hold predictive and therapeutic potential. The aim of this current review will be to describe the non-invasive procedure used in children to investigate the mechanical properties of a great elastic artery, the common carotid, and the endothelial function of the brachial artery. The accuracy of recording noninvasively the blood pressure wave contour along the arterial tree has been improved by the technique of applanation tonometry. The results obtained with these methods in previous studies are described.

Article

Mechanical properties and endothelial function

The methods include mainly 2 measurements:

1. Measurement of the common carotid artery (CCA) systolic and diastolic diameters, by evaluation of the separation of the anterior/posterior walls of an artery plotted against time during the cardiac cycle.
2. Measurement of intima and media thickness using a high resolution ultrasound system[1] (figure 1).

Figure 1: Ultrasonography of common carotid artery.

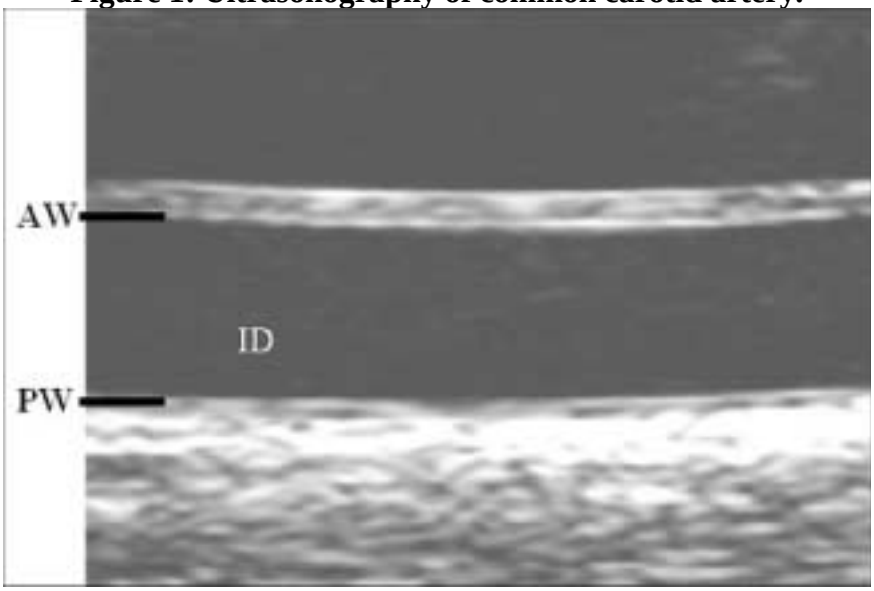

ID: internal diameter; AW: anterior wall; PW: posterior wall

Together with blood pressure measurement, this technique allows calculation of mechanical indices of the CCA: the cross sectional compliance (CSC), defined as the change in cross sectional area divided by the change in pressure (pulse pressure); the cross sectional distensibility, which is CSC divided by the diastolic cross sectional area, as a parameter of comparison of the viscoelastic properties of structures with different initial dimensions. These parameters assess the vessel as a hollow structure. The incremental elastic modulus provides information of the wall material, independent of its geometry, and defines the wall stiffness. Using the same technique, arterial endothelial and smooth muscle function are assessed. Endothelial function is determined by recording the dilator response of the brachial artery to increase blood flow generated during reactive hypereamia of the down-stream forearm, flow mediated dilation (FMD). The subject is in the supine position for 10 minutes before the first scan and remains supine throughout the study. The brachial artery is scanned in a longitudinal section, and the center of the vessel is identified when the clearest images of the anterior and posterior walls are obtained. The transmit zone is set to the level of the anterior vessel wall. Depth and gain settings are optimized to identify the lumen to vessel wall. Images are magnified with the resolution box function, leading to a television line width of 0.065 mm. Machine settings are kept constant during each study. Arterial flow velocity is measured by mean of a pulsed-Doppler signal at a 60° angle to the vessel, with the range gate (1.5 mm) in the center of the artery. Flow increase is induced by inflation of a blood pressure cuff to 300 mmHg. The cuff is released after 4 minutes, and the artery is scanned for 30 seconds before and for 90 seconds after cuff deflation, including a repeated flow velocity recording for 15 seconds after cuff release. Ten minutes later, a resting scan is recorded. Endothelium-independent dilation of the brachial artery is assessed by measuring the dilator response to a 400-µg spray of the NO donor, glyceryl trinitrate (GTN) given sublingually and the artery is scanned after 3 minutes. Results are expressed as percentage maximum change in vessel diameter from baseline.

Pulse wave analysis

The systolic and diastolic pressures represent the limits of pressure fluctuations during

the cardiac cycle. A more complete description of the complex interaction between the left ventricle and the physical properties of the arterial system is provided by the descriptive or quantitative analysis of the arterial-pulse contour. The arterial-pulse contour changes with diseases states. The arterial pressure waveform is recorded by applanating the carotid artery with a hand-held tonometer at the site of maximal pulsation. The tip of the tonometer contains a micromanometer that accurately records the pressure within the artery. The morphology is determined by wave reflection and a damped resonance, which occurs in the arterial tree, the reflected waves originating mainly from arteries and arterioles. Morphologic change in the arterial pulse contour eventually results in the forward incident pressure wave summating with backward reflected pressure wave to augment systolic blood pressure. Pulse wave analysis measures augmentation index (Aix), a parameter that reflects the degree to which central pressure is enhanced by wave reflection of the pulse wave. The systolic part of central arterial waveform is characterised by two pressure peaks. The first peak is caused by left ventricular ejection, whereas the second peak is a result of wave reflection. The difference between both pressure peaks reflects the degree to which central arterial pressure is augmented by wave reflection. Aix is defined as the increment in pressure from the first systolic shoulder (inflection point) to the second peak pressure of the aortic pressure waveform expressed as a percentage of the peak pressure (figure 2). This index is used to measure the additional load imposed on the left ventricle.[2] Aix depends, at least in part, on aortic and large artery pulse wave velocity (PWV). A higher PWV results in earlier arrival of reflected waves and, hence, increased augmentation during early systole. PWV is inversely related to arterial distensibility. Therefore, Aix has been proposed as in index of “arterial stiffness”.[3]

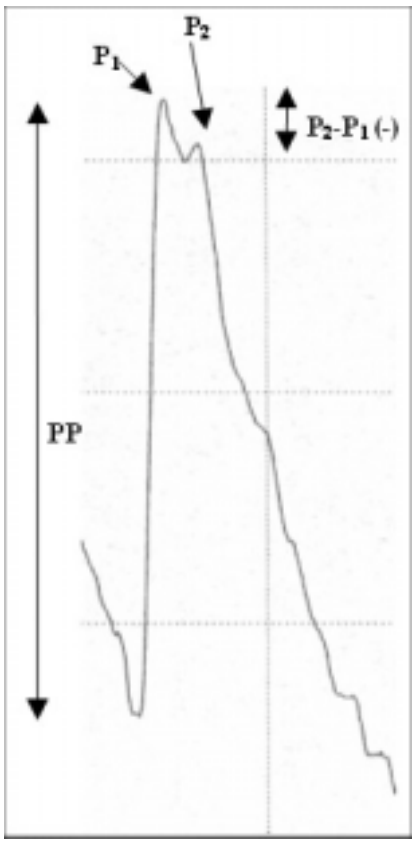

Figure 2: Waveform from the common carotid artery
P1: first systolic shoulder
P2: second inflection point (wave reflection)
IA is defined as (P2-P1)/PP

Cardiovascular risk factors in children

Familial hypercholesterolaemia

Hypercholesterolaemia is a major risk factor for atherosclerosis. The stiffness of the carotid wall can be significantly increased in male children with heterozygous familial hypercholesterolaemia.[4] Structural changes of the CCA occur very early in atherosclerosis. Therefore, they might be responsible for changes in arterial stiffness. Endothelial function has been reported to be altered in children with FH (FMD, 4.2±2.9 vs 9.0±3.1 %, P<0.001).4,5 Furthermore, the value of flow-mediated dilation was reduced for higher values LDL cholesterol in FH subjects (r=-0.40, P=0.04), suggesting a link between LDL and impairment of the endothelium-dependent, flow-mediated dilation.[4]

Obesity

Obesity has become an increasingly important medical problem in children and adolescents. Many of the outcomes associated with obesity that were previously thought of as diseases of adults are now affecting children as well. Obesity is also the most common nutritional problem among children in developed countries. There is substantial evidence that obesity in childhood lays the metabolic groundwork for adult cardiovascular disease.[6] Obesity in adolescence predicts a broad range of later health problems including an increased risk of cardiovascular morbidity and mortality. Our study provided evidence that severe childhood obesity is associated with early endothelial dysfunction (FMD, 6±3 vs 8±4 %, P<0.01; GTNMD, 17±6 vs 18±7 %, NS) and increased stiffness of elastic arteries (2.4±0.4 vs 1±0.24 mmHg.103, P<0.001). This early vascular dysfunction in children may be an early step in the development of atherosclerosis.[7]

End stage renal disease (ESRD)

End-stage renal insufficiency in children undergoing hemodialysis was shown to alter the mechanical properties of the common carotid artery: a decrease of CSC (0.11±0.04 vs 0.18±0.05 mm2.mmHg-1, P<0.01) and CSD (0.43±0.10 vs 0.82±0.20 mmHg-1.10-2, P<0.001). The incremental elastic modulus was elevated. An impairment of endothelial function was described and the Aix was increased (-24±8 vs 58±6 %, P<0.005) by an early return of the reflected pulse wave. This index was well correlated with the left ventricle mass index (r=0.55, P<0.01).[8] In adult patients who require hemodialysis, the arterial stiffness was a major predictor of all-cause and cardiovascular mortality.[9]

Arterial dysfunction after coarctation repair

The long term course after successful coarctation repair is complicated by late cardiovascular morbidity, which includes systemic hypertension at rest or/and during exercise. The responsible pathophysiological mechanisms have not been well determined. It has been reported that vascular function was different in the upper and lower limbs. Reduced flow mediated dilation (FMD, 5±3 vs 7±3 %, P<0.01) and glyceryltrinitrate (GTN, 16±8 vs 23±9 %, P<0.01) responses were observed in the upper limb.[10] In contrast, lower limb arteries showed preserved FMD and GTN.[11,12] This pattern of persistent abnormalities of conduit arteries in the upper limb during long-term follow-up suggests that aortic coarctation is associated with extensive arterial dysfunction and that, at least in part, vascular changes are acquired as a result of the abnormal hemodynamics present in the upper part of the body before surgery.

Parenteral nutrition

In children, total or partial parenteral nutrition is a well-established intervention in acute or chronic illnesses that limit oral feeding, impair digestive function and threaten nutritional status. The repercussions of parenteral nutrition on structure and function of arteries in children are an increase in the CCA stiffness (1.8±0.4 vs 1.4±0.5 mmHg.103, P<0.05) associated with an impairment of the endothelium function (FMD, 6±3 vs 8±3 %, P<0.05; GTNMD, 22±9 vs 25±9 %, NS).[13] The exact mechanism through which parenteral nutrition might accelerate the formation of atheromatous lesions is unclear. The deleterious effects of parenteral nutrition on endothelial function and on CCA stiffness that we observed could reflect the additive role of lipid infusion and hyperinsulinemia. The relationship between dyslipidemia and vascular endothelium has been well established, not only in adults but also in children. Substrate competition during parenteral nutrition can lead to insulin resistance.[14] Insulin resistance syndrome, with its components hyperinsulinemia, obesity, hypertension and hyperlipidemia has been recognized as a major precursor of atherosclerostic cardiovascular disease in adults.[15]

Williams syndrome

Williams syndrome, easily recognized of its typical facial appearance, is characterised by microdeletion of chromosome 7q 11.23. The role of disruption of elastin in producing thickening of the arterial wall has been made evident in a mouse model lacking elastin.[16,17] Elastin not only has a structural role in the extracellular matrix, it also controls smooth muscle proliferation during arterial development. The cross sectional compliance of the CCA of Williams was not modified but there was evidence of a low arterial stiffness (0.74±0.2 vs 1.4±0.5 mmHg.103, P<0.001).[18] A major increase of the intima media thickness was described (0.6±0.07 vs 0.5±0.03 mm, P<0.001) as a characteristic arterial phenotype (figure 3).

Figure 3: Ultrasound of common carotid artery
On the left: William's syndrome. Note the significant increase of the intimal medial thickness when compared with the control on the right

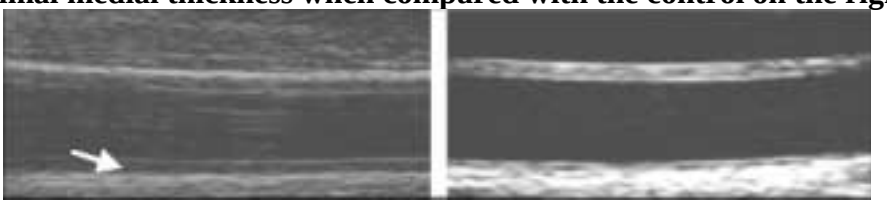

In conclusion, physicians need to need to be aware that measurement of the mechanical properties of arteries and endothelial function will provide information for guiding the clinical decision making process. The application of the technique will contribute to assess the arterial function in congenital or acquired abnormalities of arterial wall structures, as seen in pathology of elastin and collagen, and in metabolic disorders such as diabetes. The assessment of arterial function may help to define clinical risk stratification and guide therapeutic interventions.

References

1. Graf S, Gariepy J, Massonneau M, Armentano RL, Mansour S, Barra JG, Simon A, Levenson J. Experimental and clinical validation of arterial diameter waveform and intima media thickness obtained from B-Mode ultrasound image processing. Ultrasound in Med & Biol. 1999;25:1353-1363
2. Saba PS, Roman MJ, Pini R, Spitzer M, Ganau A, Devereux RB. Relation of arterial pressure waveform to left ventricular and carotid anatomy in normotensive subjects. J Am Coll Cardiol 1993;22:1873-1880
3. Nichols WW, Singh BM. Augmentation index as a measure of peripheral vascular disease state. Curr Opin Cardiol 2002;17:543-551
4. Aggoun Y, Bonnet D, Sidi D, Girardet JP, Brucker E, Polak M, Safar ME, Levy BI. Arterial mechanical changes in children with familial hypercholesterolemia. Arterioscler Thromb Vasc Biol 2000;20:2070-2075
5. Sorensen KE, Celermajer DS, Georgapoulos D, Hatcher G, Betteridge DJ, Deanfield JE. Impairement of endothelium-dependent dilation is an early event in children with familial hypercholesterolaemia and is related to the Lp (a) level. J Clin Invest 1994;93:50-55
6. Srinivasan SR, Bao W, Wattigney WA Berenson GS, Adolescent overweight is associated with adult overweight and related multiple cardiovascular risk factors: the Bogalusa Heart Study. Metabolism 1996;45:235–240
7. Tounian P, Aggoun Y, Dubern B, Varille V, Guy-Grand B, Sidi D, Girardet JP, Bonnet D. Presence of increased stiffness of the common carotid artery and endothelial dysfunction in severely obese children: a prospective study. Lancet 2001;358:1400-1404.
8. Aggoun Y, Niaudet P, Laffont A, Sidi D, Kachaner J, Bonnet D. Cardiovascular impact of end-stage renal insufficiency in children undergoing hemodialysis. Arch Mal Cœur Vaiss 2000;93:1009-1013
9. Blacher J, Guerin AP, Pannier B, Marchais SJ, Safar ME, London G. Impact of aortic stiffness on survival in end-stage renal disease. Circulation 1999;99:2434-2439
10. Aggoun Y, Sidi D, Bonnet D. Arterial dysfunction after treatment of the coarctation of the aorta. Arch Mal Cœur Vaiss 2001;94:785-789
11. De Divitiis M, Pilla C, Kattenhorn M, Zadinello M, Donald A. Leeson P, Wallace S, Dip HE, Redington A, Deanfield JE. Vascular dysfunction after repair of coarctation of the aorta. Impact of early surgery. Circulation 2001;104:I-165-I-170
12. Gardiner HM, Celermajer DS, Sorensen KE, Georgakopoulos D, Robinson J, Thomas O, Deanfield JE. Arterial reactivity is significantly impaired in normotensive young adults after successful repair of aortic coarctation in chilhood. Circulation 1994;89:1745-1750
13. Aggoun.Y, Colomb V, Turanlahti M, Corriol O, Goulet O, Sidi D, Ricour C, Bonnet D. Endothelial function and mechanical properties of the common carotid artery in children on parenteral nutrition. Ped Res 2002 (in press).
14. Vigili de Kreutzenberg S, Lisato G, Riccio A, Giunta F, Bonato R, Petolillo M, Tiengo A, Del Prato S. Metabolic control during total parenteral nutrition: use of an artificial endocrine pancreas. Metabolism 1988;37:510-513

15. Lehr HA, Becker M, Marklund SL, Hubner C, Arfors KE, Kohlschutter A, Messmer K. Superoxyde-dependent stimulation of leukocyte adhesion by oxidatively modified LDL in vivo. Arterioscler Thromb. 1992;12:824-829
16. Li DY, Brooke B, Davis EC, et al. Elastin is an essential determinant of arterial morphogenesis. Nature 1998;393:276-280
17. Li DY, Faury G, Taylor DG, et al. Novel arterial pathology in mice and humans hemizygous for elastin. J Clin Invest 1998;102:1783-1787
18. Aggoun Y, Sidi D, Levy BI, Lyonnet S, Kachaner J, Bonnet D.Mechanical properties of the common carotid artery in Williams syndrome. Heart 2000;84:290-293

Contact information

Prof. Maurice Beghetti
Professor of Paediatric Cardiology
Head, Cardiology Unit
Hôpital des Enfants
6 rue Willy Donzé
CH 1211 Geneva 14 - Switzerland
maurice.beghetti@hcuge.ch

© Images in
Paediatric Cardiology
1999-2003